


COSMETIC VEIN PRACTICE: Secrets to Success

Lorraine Loretz, DPM, MSN, NP
UMass Memorial Healthcare

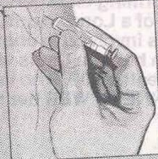



1. Understand the expectations.

HOW IT WORKS

1 A special foam solution is injected into affected veins. Treatment takes less than an hour and is virtually pain-free.



2 Foam is mixed with air, to create a texture consisting of very small bubbles. This helps facilitate its flow through the veins. The mixture then begins to dissolve lining of veins, causing them to break up and disappear.



A DOCTOR is pioneering a new treatment for varicose veins without the need for painful surgery. Traditionally, the large, ugly, blue veins that affect men and women have to be removed by surgery under general anaesthetic.

But now a British vein specialist is treating patients with a series of injections taking just an hour.

The treatment is almost pain-free, allowing patients to pop into a clinic for treatment during their lunch break. It involves injecting a special foam solution that dissolves the lining of the veins, causing them to disappear.

Vein surgeon Philip Coleridge Smith, who brought the technique to the UK, claims the treatment will work for two-thirds of patients who would have needed an operation.

He says: 'A Spanish doctor came up with the idea of using foam to force the blood out of the vein, so the chemical used didn't lose its potency.'

The treatment has been used in many countries, where the success rate for the injections is around 90 per cent. Occasional follow-up treatment may be needed if new veins start to appear.

At present, foam injections are on offer from only a handful of vein surgeons in the UK while doctors learn to use the new technique.

Varicose veins occur because of faulty valves that don't close properly.

Blood is sent in the wrong direction, forcing it to pool up and bulge in the veins of the leg with no escape. They tend to become painful and can, in some cases, lead to leg ulcers.

Usually, Mr Coleridge Smith can tell within a few minutes if a patient is suitable for

In one hour my varicose veins were cured – by injections of foam...

By **MARTYN HALLE**

injection treatment. He says: 'I use an ultrasound machine to map the veins to see how many need treating.'

'Patients are only pointed in the direction of surgery if the veins are too large or if there are too many to treat.'

'Even if a patient has a fair number we can normally spread the treatment over a couple of appointments. I would do about half a dozen injections per leg during an hour session. There is very little pain, although we do give a local anaesthetic.'

Patients feel little discomfort after treatment, although they may suffer a dull ache around the injection sites.

They have to wear a

compression bandage for one week after treatment and then an elastic stocking for a further week.

By contrast, conventional surgery often involves a stay in hospital and up to two to three weeks of work.

Mr Coleridge Smith carries out the injections privately, although they will be available on the NHS eventually.

MANY patients are finding that even if they have painful varicose veins, local health authorities will not sanction the treatment on the NHS, forcing many to go private.

Private surgery costs about £2,000-3,000 compared with £800-£1,000 for injections.

One patient who is delighted not to have had surgery is

24-year-old Joanna Pontin, of High Wycombe, Bucks, who developed varicose veins two years ago.

She says: 'I had veins on the back of both my legs and on one of my thighs. They were unsightly and ached a lot. They got worse while I was pregnant with my son Ethan, who is now two.'

'Mark, my husband, said that if they were bothering me I should get them treated. I had two sessions in the summer and was delighted with the outcome. The injections were virtually painless and I had very little discomfort.'

'Now, there is only the faintest discolouration left over from the bruising, and no sign of any veins.'

■ **FOR more information, contact the British Vein Institute on 0800 7836106 or go to www.bvi.uk.com.**

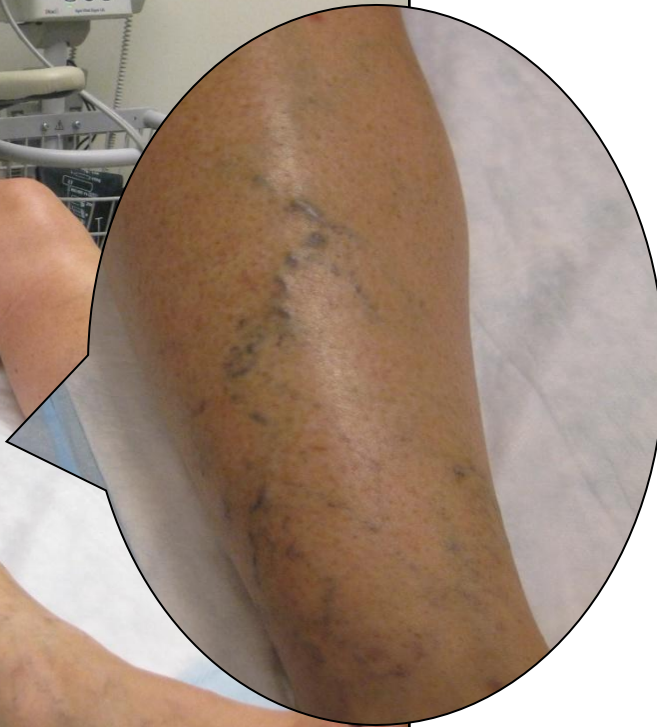
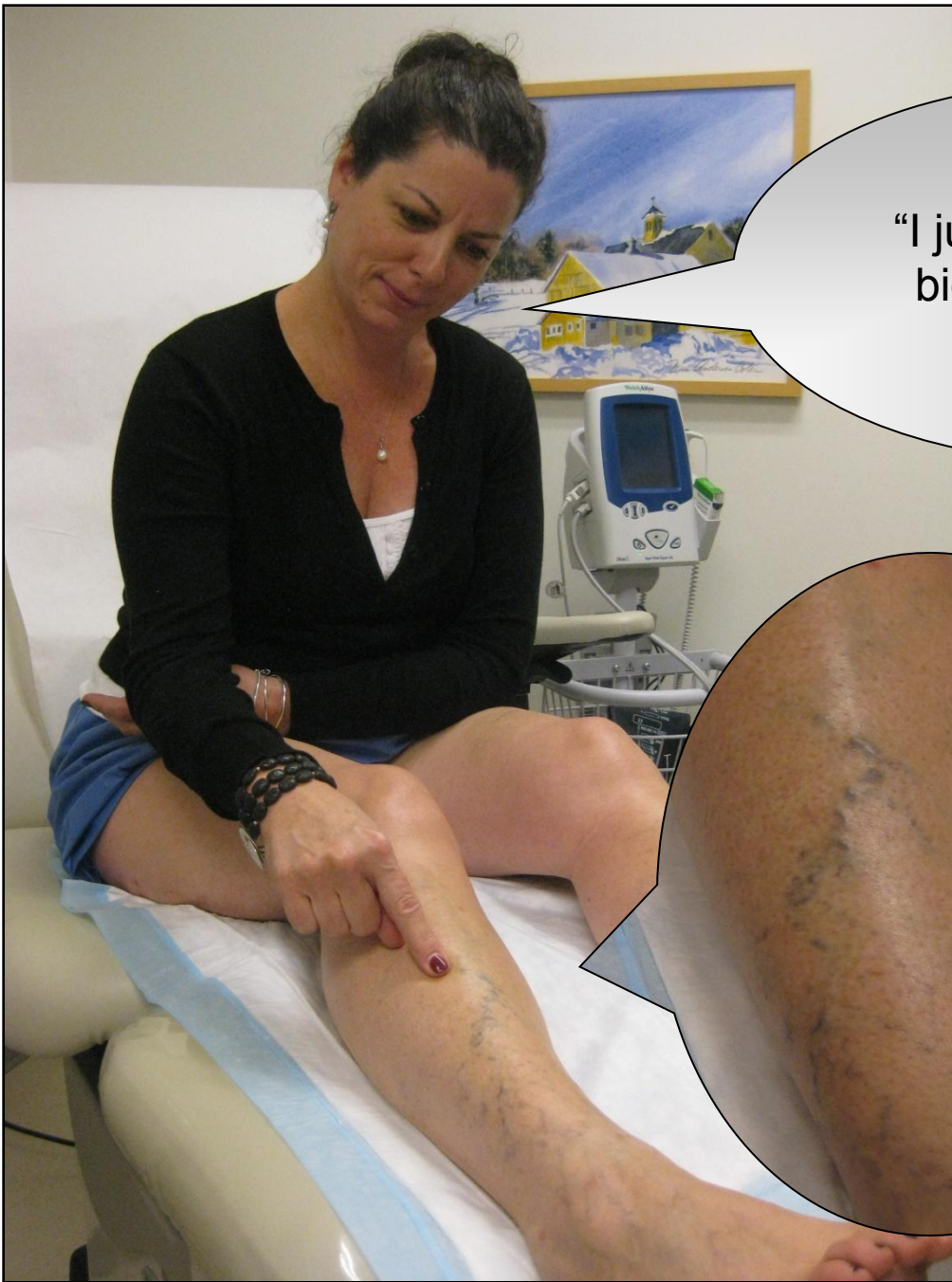
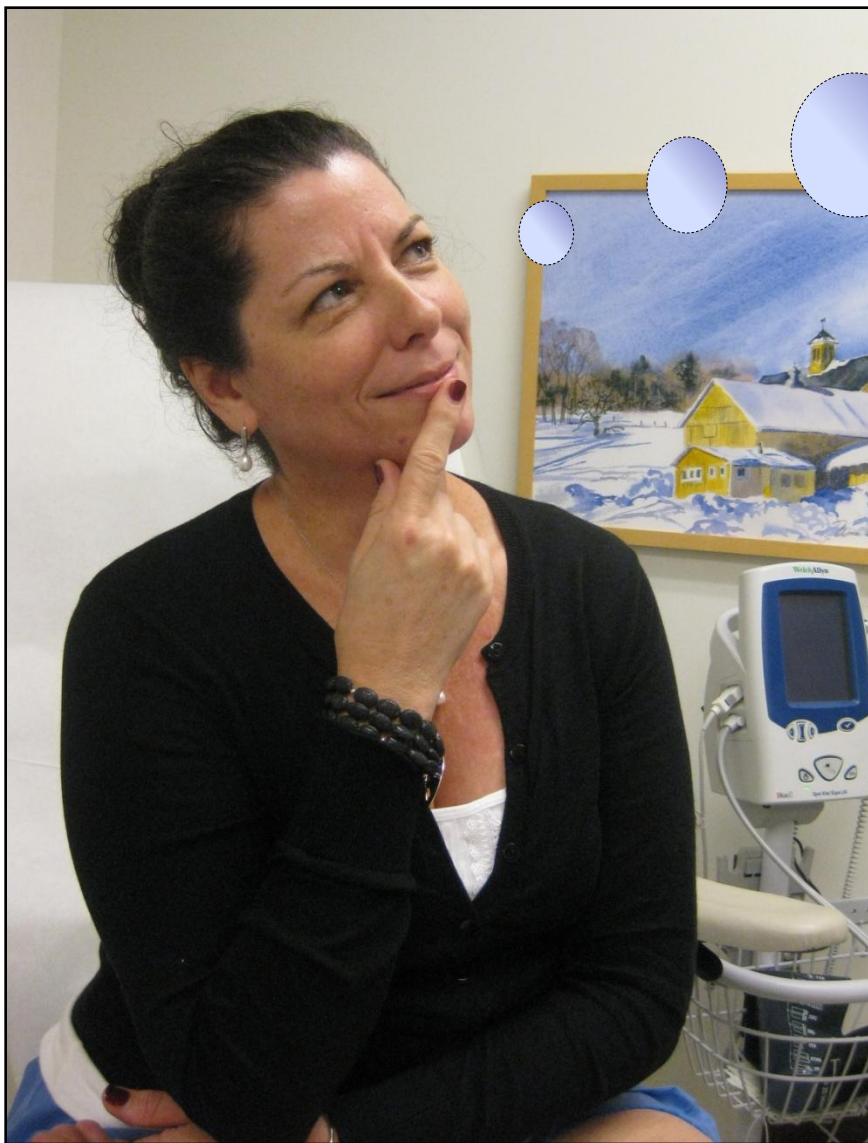Treatment was not in vain: Joanna Pontin was thrilled with the innovative injections

Picture: MARK RICHARDS

She says . . .

“I just want this one
big vein gone . . .”





But she's thinking . . .

Expectations vs Reality



- Discuss the number of treatment sessions needed to obtain cosmetic satisfaction
- Discuss the time required to achieve cosmetic improvement
- Discuss cost of treatment
- Discuss potential adverse reactions/outcomes
- Review patient medications
- Obtain informed consent
- Take photos at each treatment to monitor progress
- Emphasize the importance of using compression after treatment



2. Know the anatomy and physiology of the venous system.

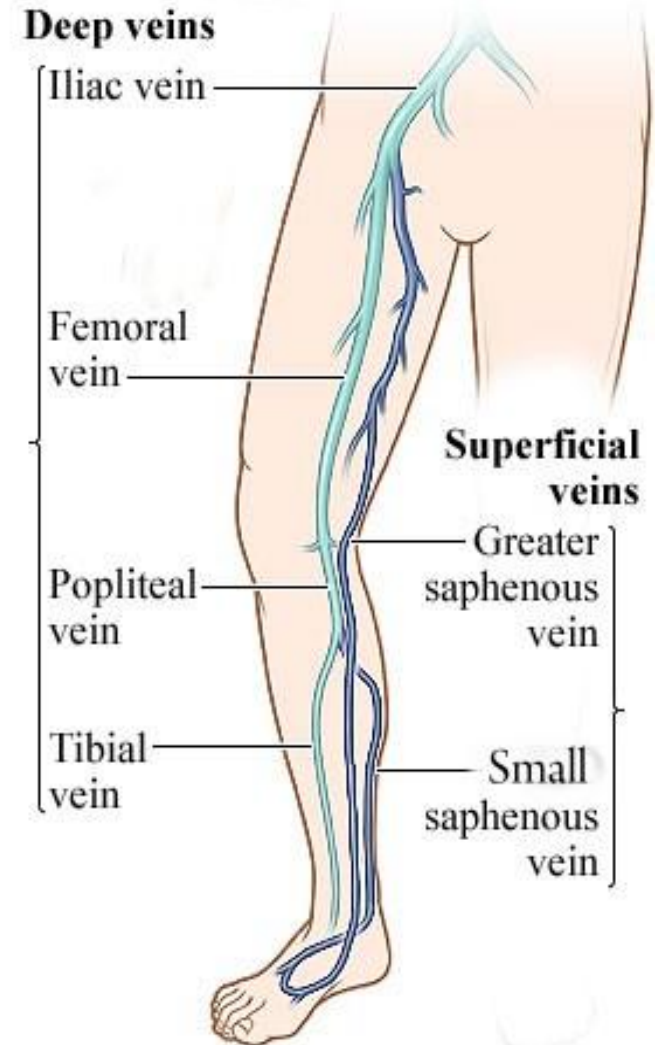
Anatomy and physiology of the venous system in the lower extremity



- **Deep venous system:** the channel through which 90% of venous blood is pumped out of the legs
- **Superficial venous system:** the collecting system of veins
- **Perforating veins:** the conduits for blood to travel from the superficial to the deep veins
- **Musculovenous pump:** Contraction of foot and leg muscles pumps the blood through one-way valves up and out of the legs

Deep Venous System

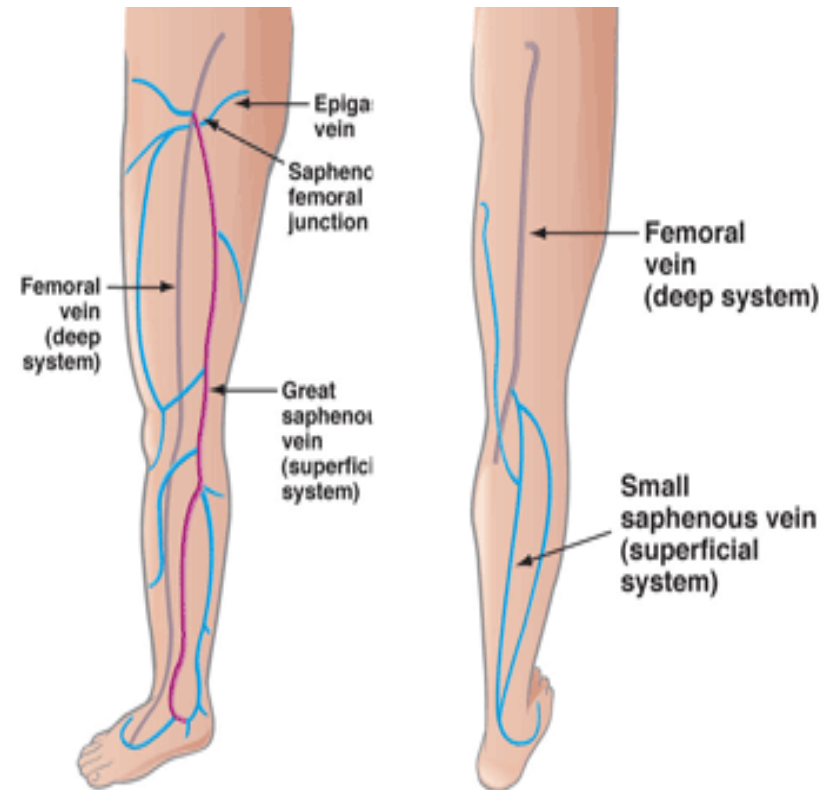
- Named by associated arteries
- Predictable anatomy
- Causes much of the morbidity
 1. DVT/PE
 2. Severe leg swelling
 3. Ulcerations
- Medical management
 - Anticoagulation
 - Thrombolytic therapy
 - Elevation and compression
 - Wound care



Superficial Venous System



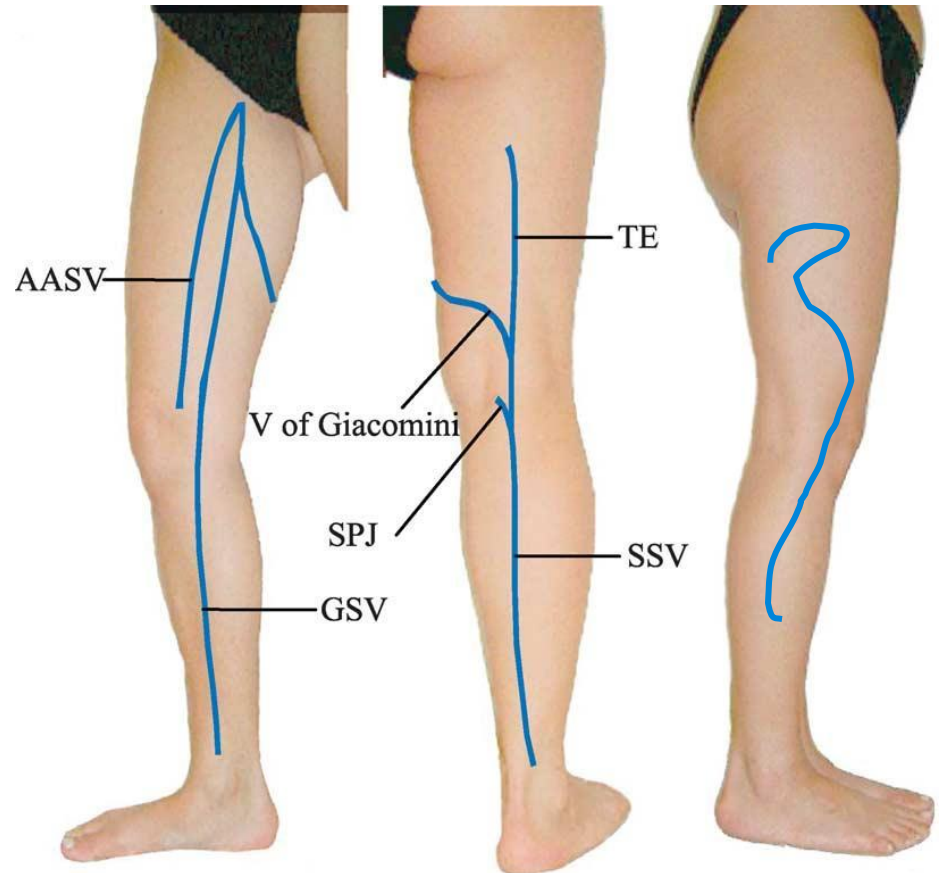
- Two main named branches
 - Great saphenous
 - Small saphenous
- Perforators connect superficial and deep systems
- Highly variable anatomy
- Many unnamed branches and tributaries



Other Important Branches



- Anterior Accessory Saphenous vein
- Giacomini vein
- Subdermal plexus of Albanese



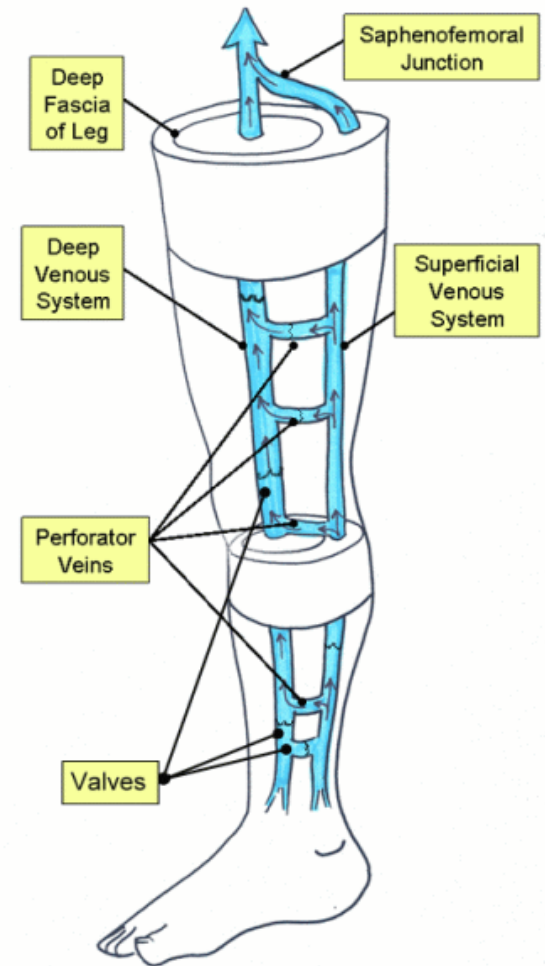
Normal Venous Flow in the Leg



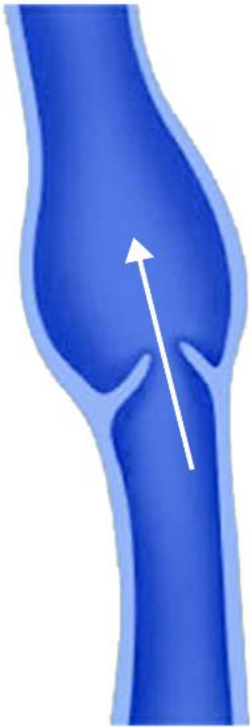- Normal Flow
 - Superficial veins → deep veins
 - Feet → Heart

• Superficial vein disease always starts with abnormal valves and interruption to normal flow →

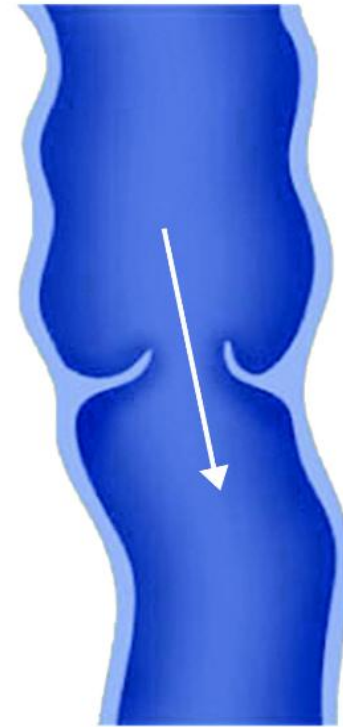
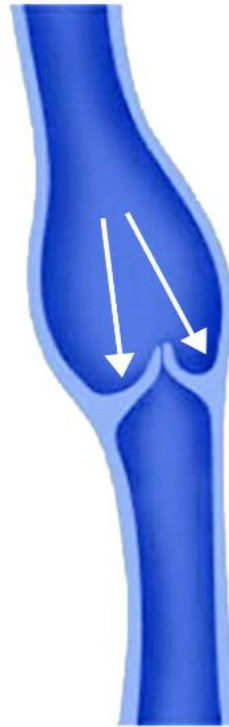
Venous Reflux



Venous Reflux



Healthy Vein Valves
& Correct Blood Flow



Damaged Vein Valve
& Incorrect Blood Flow

Pathophysiology



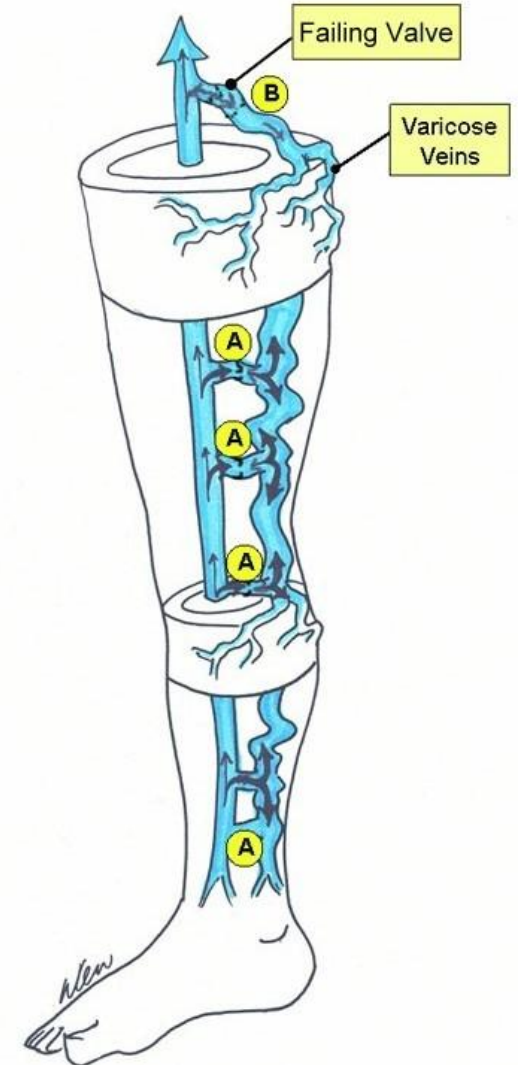
- Valve leaflets allow unidirectional flow upward or inward
- Prolonged exposure to increased pressure causes valves to become incompetent and no longer close properly
- Dilation of vein wall prevents opposition of valve leaflets leading to valve insufficiency and reflux
- Blood regurgitates into superficial veins, pools and stretches the vein
- Tributaries become dilated, blue, bulging and painful. This is venous reflux disease. Varicose veins develop, producing venous deformity and further dilation.

Abnormal flow = Venous Reflux



Damaged Valves:

1. Blood flows to the skin
2. Blood is pushed distally and proximally
3. Closed loop recirculation
4. Blood is retained in the leg
 - Increased volume of blood
 - Increased venous pressure
 - Veins dilate





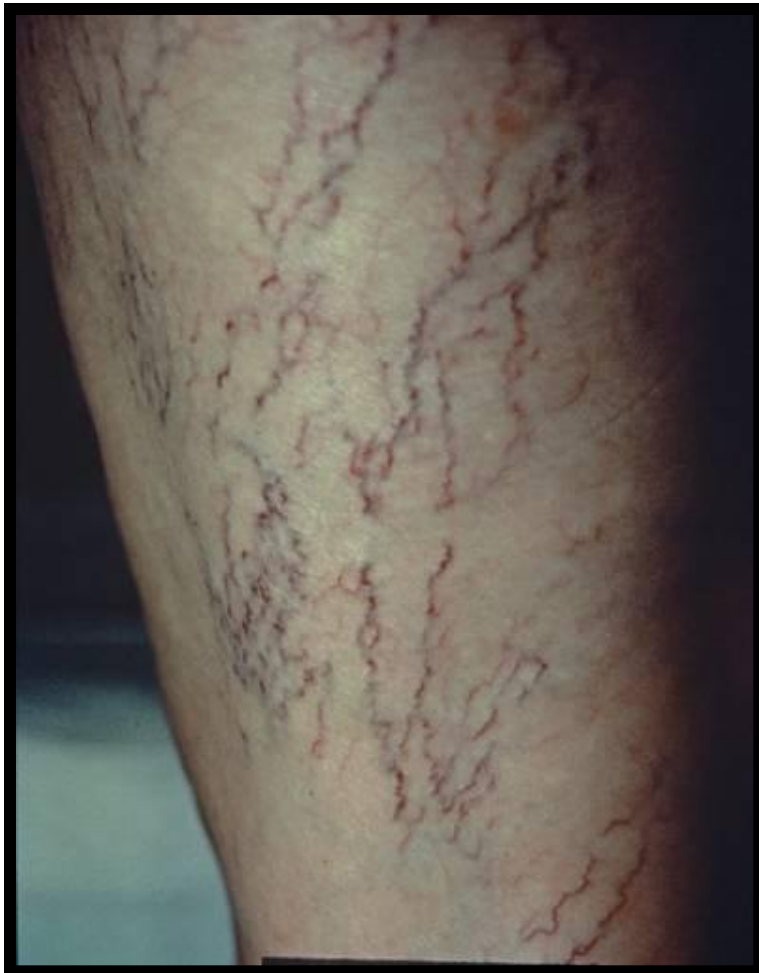3. Develop your 'reflux radar'.



CEAP Classification

- “**C**” = Clinical
 - C0 - no visible venous disease
 - C1 - telangiectasias or reticular veins
 - C2 - varicose veins
 - C3 - edema
 - C4 - skin changes without ulceration
 - C4a – pigmentation or eczema
 - C4b – LDS or atrophie blanche
 - C5 - skin changes with healed ulceration
 - C6 - skin changes with active ulceration
- “**E**” = Etiology (primary vs. secondary)
- “**A**” = Anatomy (defines location of disease within superficial, deep and perforating venous systems)
- “**P**” = Pathophysiology (reflux, obstruction, or both)

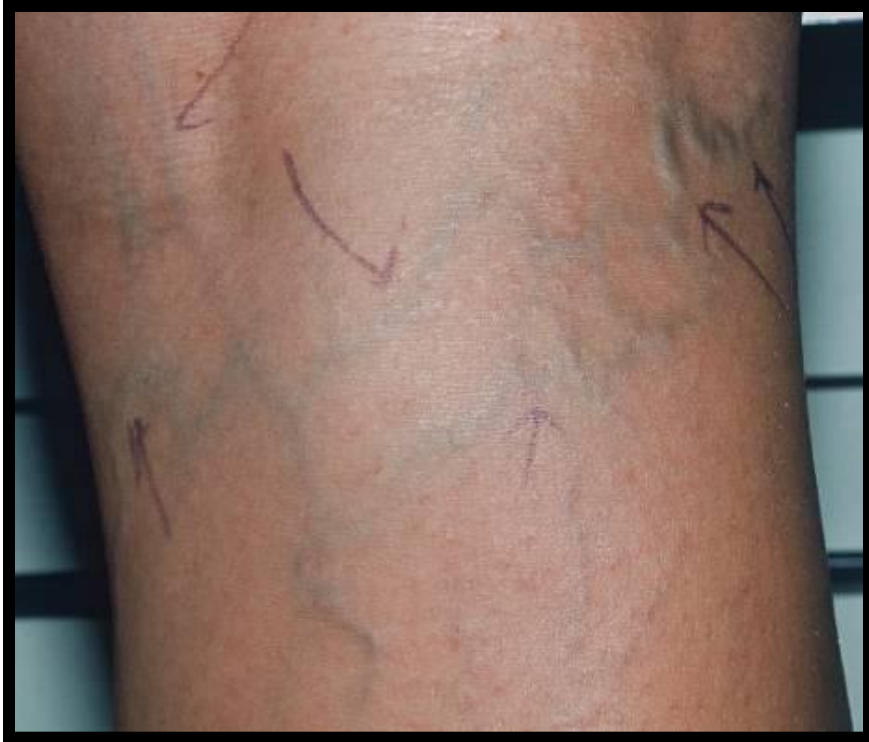
Telangiectasias



- Also known as “spider veins” due to their appearance
- Evolve from capillaries or early venules
- Blue-to-red
- < 1 mm in caliber
- Very common, especially in women
- Increase in frequency with age
- 85% of patients are symptomatic*
- May indicate more extensive venous disease

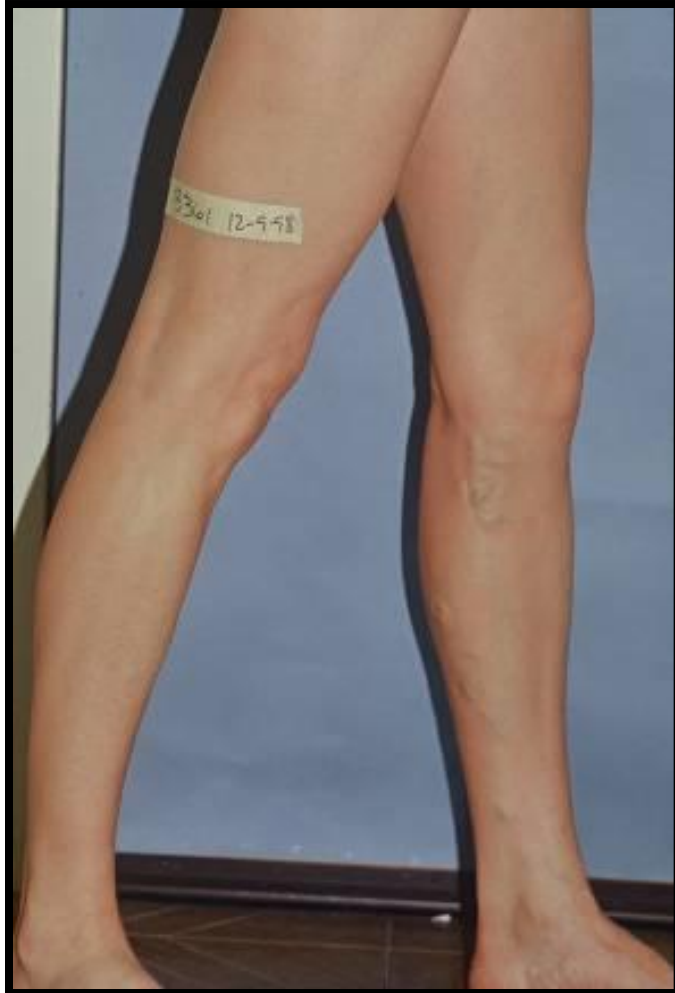*Weiss RA and Weiss MA *J Dermatol Surg Oncol.* 1990 Apr;16(4):333-6.

Reticular Veins



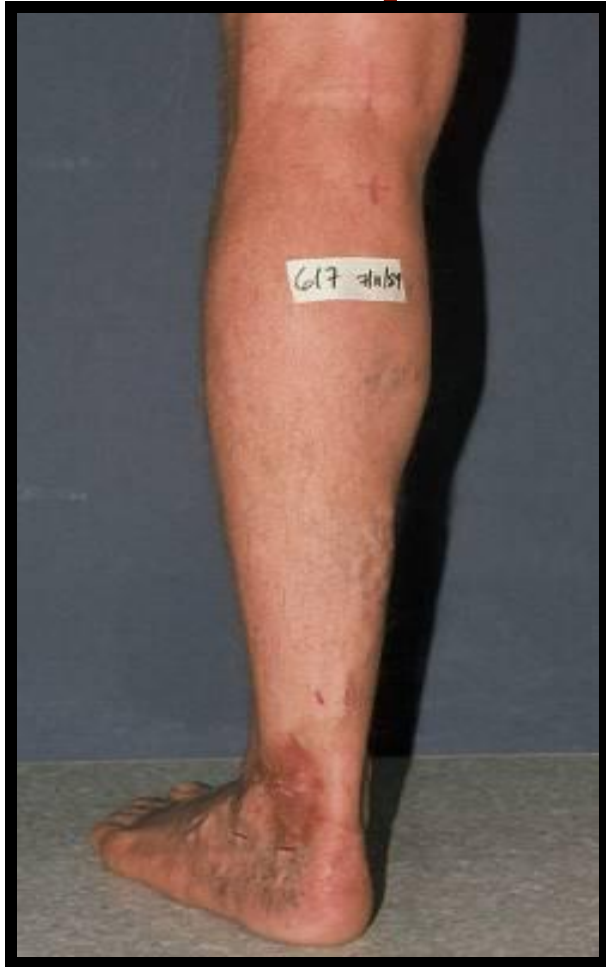- Dilated bluish intradermal veins
- Frequently associated with clusters of telangiectasias
- 1mm – < 3mm in diameter
- Usually tortuous
- Venulectasias, blue-veins, intradermal varicies
- May be symptomatic, especially in dependent areas of leg

Varicose Veins – Great Saphenous Distribution



- Most common finding in patients with varicose veins
- Varicosities most commonly along the medial thigh and calf but cannot assume location indicates origin
- Up to 20% of patients are at risk of ulceration; presence of skin changes is predictive
- Skin changes may be seen along the medial ankle

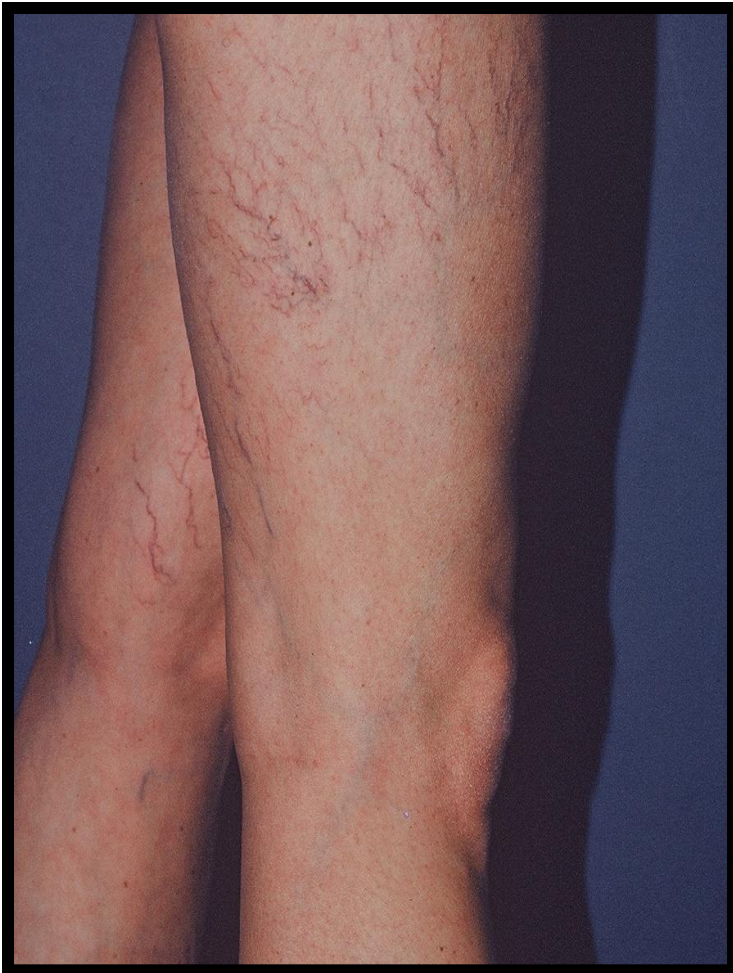Varicose Veins – Small Saphenous Distribution



- Less frequent than Great Saphenous involvement
- Varicosities may be seen on the posterior calf and lateral ankle
- Skin changes may be seen along the lateral ankle
- If have GSV reflux, may improve with fixing GSV reflux as well as SSV reflux



Lateral Subdermic Plexus



- Very common, especially in women
- Superficial veins with direct perforators to deep system
- Remnant of embryonic deep venous system

Approach to Venous Disease



- Patients often have combination of varicose, reticular veins and telangiectasias
- Treatment method depends on type of vein (i.e. varicose vs reticular vs spider) and presence or absence of venous reflux
- Often more than one type of treatment may be required



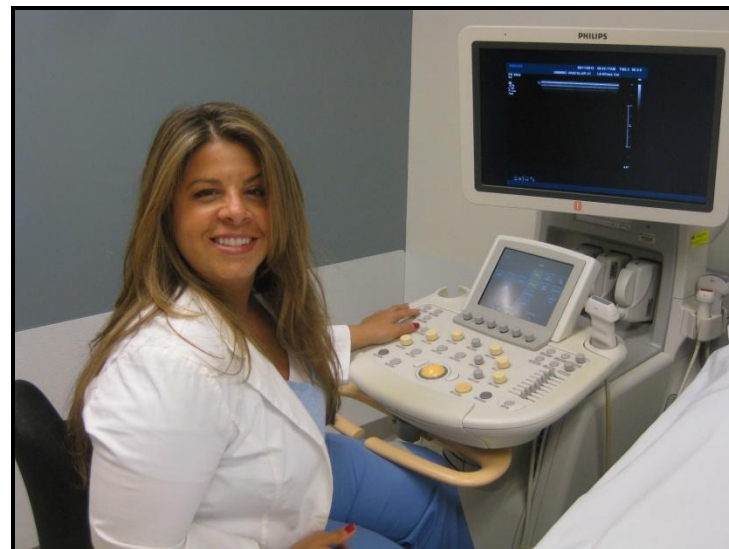4. Have access to a good vascular lab.

Accredited Vascular Lab

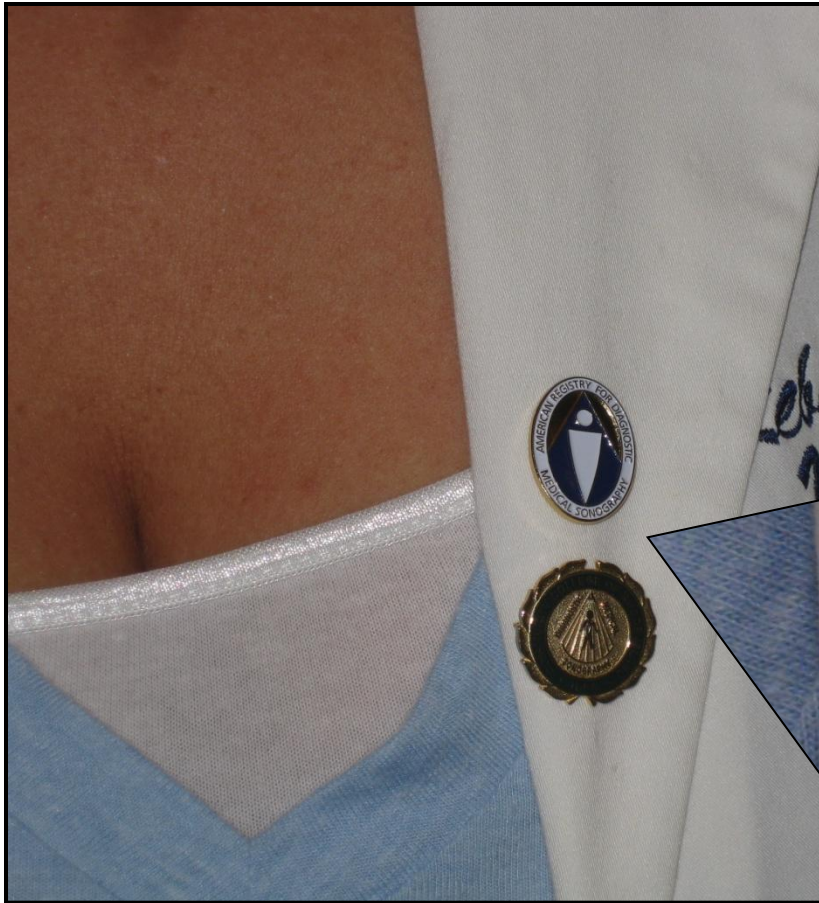


IAC Vascular Testing — formerly the Intersocietal Commission for the Accreditation of Vascular Laboratories (ICAVL)

<http://www.intersocietal.org/vascular/>



... with a Certified Vascular Lab Technician



When To Order a Reflux Study?

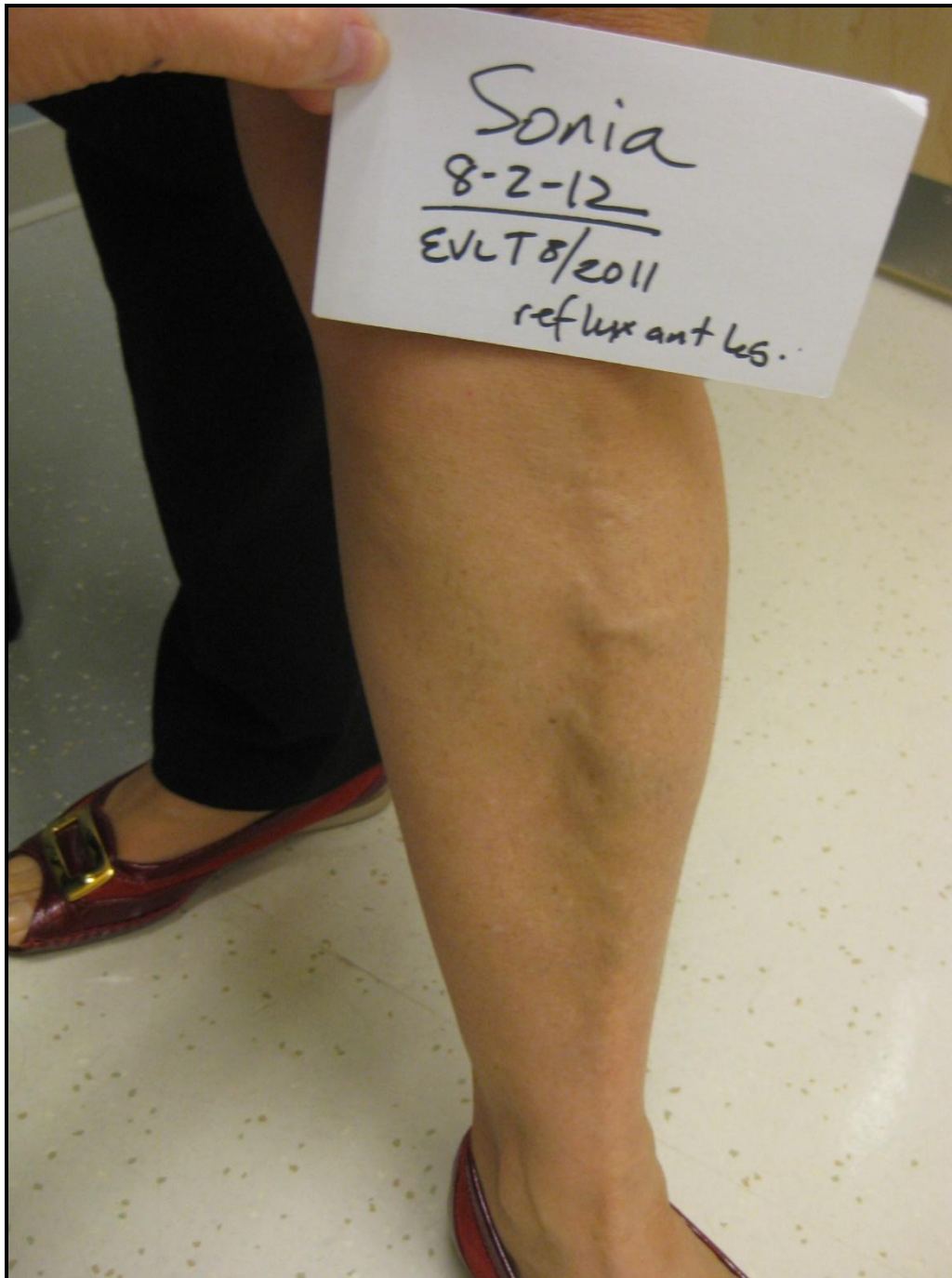


- Varicosities > 3mm in distribution of GSV, SSV, Accessory Saphenous Vein, Giacomini vein or branches of these
- Large clusters of spider or reticular veins that are symptomatic
- Symptoms out of proportion to appearance

Approach to Venous Disease



- Assess for Symptoms:
 - Pain, aching, swelling of veins
 - Burning, throbbing, tiredness, itching, numbness, heaviness, redness, ulceration
- Assess for GSV or SSV reflux with ultrasound
- Assess patient cosmetic desire and expectation
- Fix the big veins first



Sonia
8-2-12
EVL T8/2011
reflux ant les.





5. Choose your weapons.

Treatment Modalities: General



- Compression Stockings: 20-30 mmHg
- Sclerotherapy
- Ambulatory phlebectomy
- EVLT
- RF ablation
- US guided sclerotherapy
- Vein ligation and stripping
- Transdermal laser

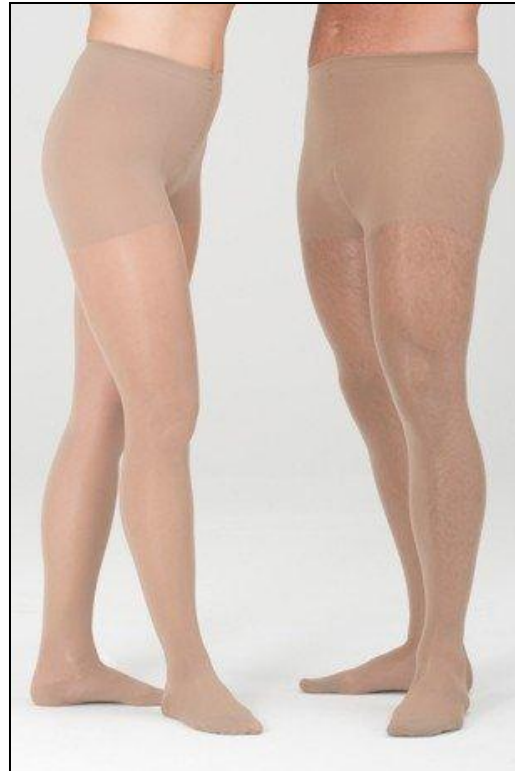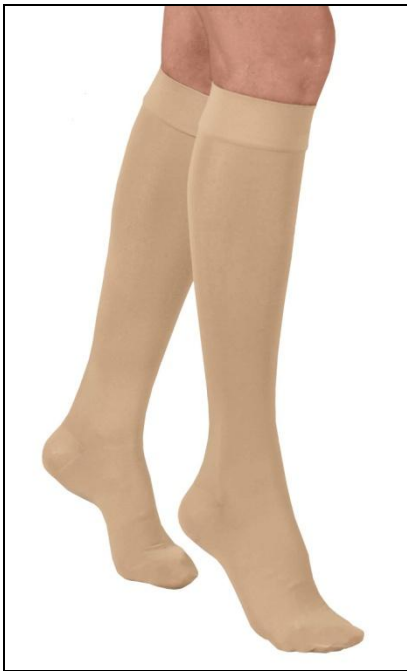Treatment Modalities: Conservative



- Compression Stockings: 20-30 mmHg:
 - Noninvasive but very hot and uncomfortable
 - May be insufficient in relieving symptoms
 - No data on efficacy of varicose vein prevention
 - Will not eliminate veins
- Reduced standing activity
- Leg elevation
- Weight reduction

Compression Stockings

Premium stockings: Juzo, Sigvaris, Medi, Jobst





Treatment Modalities: Varicose Veins with Reflux

- Ambulatory phlebectomy
- EVLT
- RF ablation
- US guided sclerotherapy
- Vein ligation and stripping

Treatment Modalities: Small Veins



Reticular:

- Higher concentration sclerosing agent
- Foam sclerotherapy
- Transdermal laser does not work very well

Telangiectasias:

- Lower concentration sclerosing agent
- Transdermal laser

Sclerotherapy Mechanism



- 1) Injection of a sclerosant into the vein
- 2) Sclerosant causes endothelial and vein wall damage
- 3) Vein fibrosis occurs and clot forms
- 4) Clot is eventually resorbed and vein is obliterated

Goal of Sclerotherapy



Inject vein with **lowest quantity** of sclerosing agent and **lowest concentration** as possible to produce:

- Inflammatory reaction
- Eventual fibrosis
- Cosmetic and symptomatic relief



6. Know your agents.

Sclerosing Agents



- The best solution to use is the one you are most familiar with.
- Agents available:
 - polidocanol - POL (Asclera[®]) *
 - sodium tetradecyl sulphate – STS (Sotradecol[®])*
 - sodium morrhuate (Scleromate[®])*
 - hypertonic saline
 - glycerin
 - ethanolamine oleate (ETH) (Ethamolin[®])**

*Only agents FDA approved for use in US

**FDA approved only for esophageal varices

Sclerosing Agents



Sotradecol[®] (sodium tetradecyl sulphate - 1% and 3%)

- Safe efficacy profile
- Less burning
- Less hyperpigmentation
- Lower allergy risk
- Less necrosis with extravasation
- If diluted properly has minimal side effects
- Dilute with NS to 0.07 to 0.5% for most veins
- Maximum dosage = 10 cc (1%)

Sotradecol®

Concentration and Volume



Telangiectasias (<1mm):

0.1%-0.25% STS, 0.5% POL

Volume ~ 0.2 cc

Reticular Veins (1 - <3mm):

0.25%-0.5% STS +/- foam, 1% POL

Volume ~0.2-0.5 cc

Varicose Veins (3 - 5mm):

0.5% - 1%, or foam STS, POL-not indicated

Volume ~0.5 – 1 cc



Sclerosing Agents

Asclera[®] (polidocanol 0.5% and 1%)

- Safe efficacy profile
- Virtually no burning or pain
- Minimal to no hyperpigmentation
- Moderate allergy risk
- Minimal necrosis with extravasation
- Indicated to treat uncomplicated spider veins (varicose veins ≤ 1 mm in diameter) and uncomplicated reticular veins (varicose veins 1 to 3 mm in diameter) in the lower extremity. It has not been studied in larger varicose veins > 3 mm in diameter. Maximum dosage = 10 cc
- No study using 'foam' technique; not diluted for injection

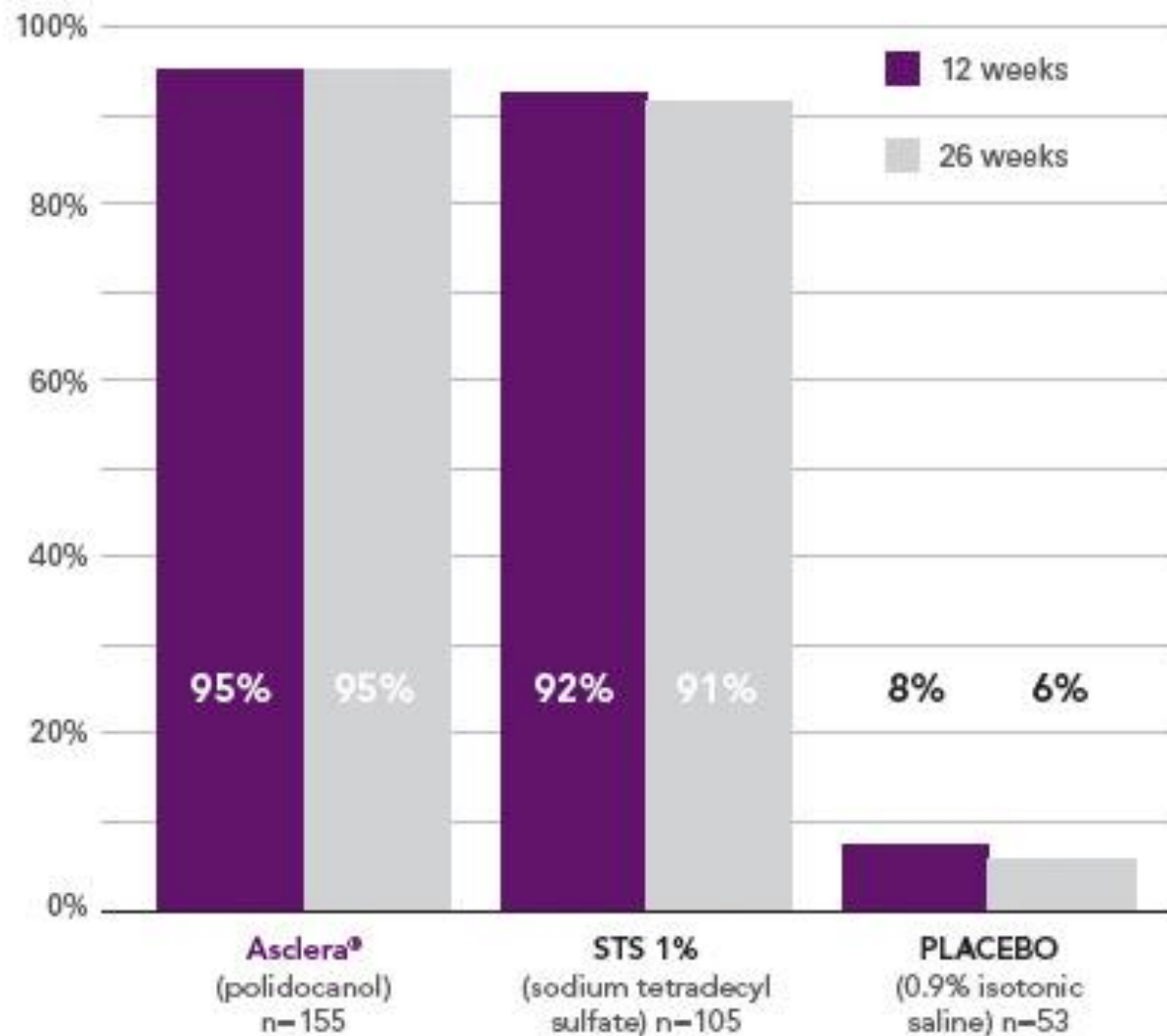
EASI Study – Adverse Effects



	ASCLERA (180 patients)	STS 1% (105 patients)	Placebo (53 patients)
Injection site hematoma	42%	65%	19%
Injection site irritation	41%	73%	30%
Injection site discoloration	38%	74%	4%
Injection site pain	24%	31%	9%
Injection site pruritus	19%	27%	4%
Injection site warmth	16%	21%	6%
Neovascularisation	8%	20%	4%
Injection site thrombosis	6%	1%	0%

Ultrasound examinations at one week (3 days) and 12 weeks (2 weeks) after treatment did not reveal DVT in any treatment group.

TREATMENT SUCCESS RATES



¹ Treatment success was rated on a 5-point scale (1 = worse than before, 2 = same as before, 3 = moderate improvement, 4 = good improvement, 5 = complete treatment success) by a blinded panel.

Other Agents



Hypertonic Saline

- Introduced as vein sclerosant in 1926
- Very painful when injected
- Significant necrosis on extravasation
- Higher incidence hyperpigmentation
- Rapid venous dilution results in less efficacy than other agents

Glycerin

- Rapid clearance of telangiectasias 0.2-0.4 mm
- More bruising than other agents
- Not FDA approved



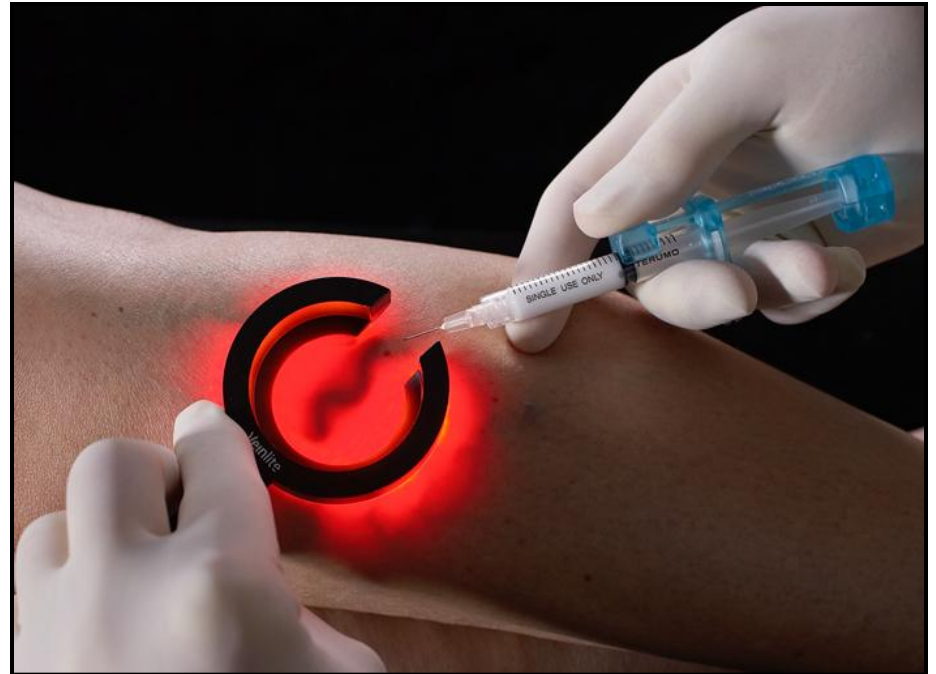7. Use a light.



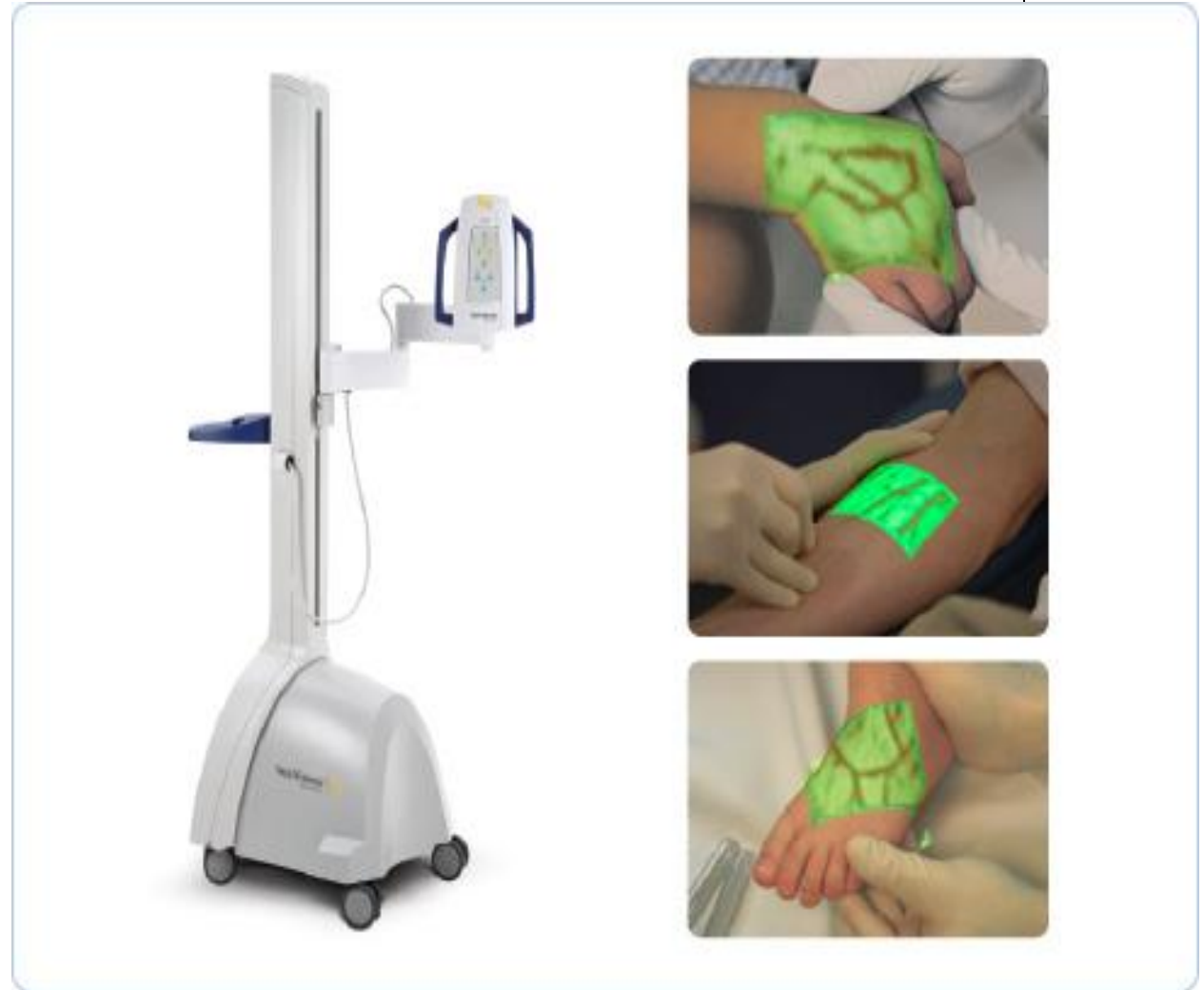Image Assistance

- Varicose Veins:
 - Best visualized by ultrasound
- Reticular / feeder veins:
 - Best visualized by vein viewer (to 8 mm depth) or veinlite (to 5 mm depth)
- Spider veins:
 - Best visualized by naked eye or veinlite

Veinlite[®] – to 5 mm



Vein Viewer[®] – to 8 mm



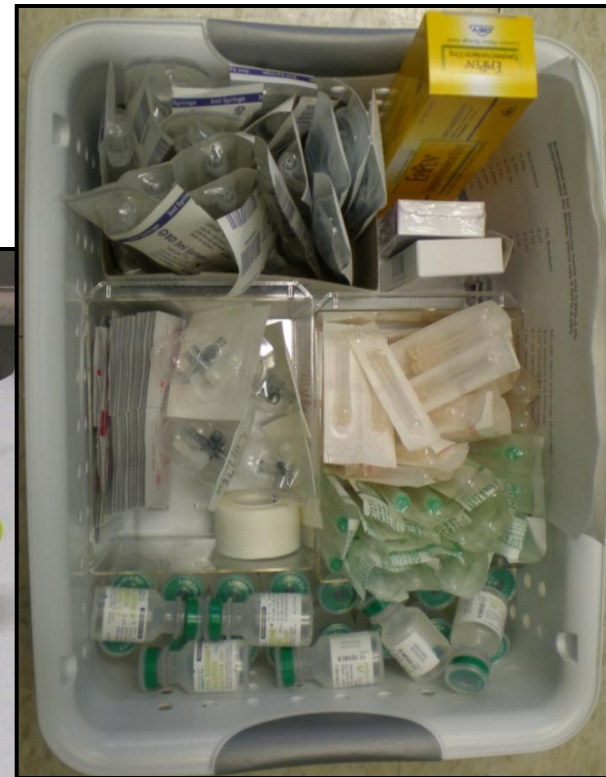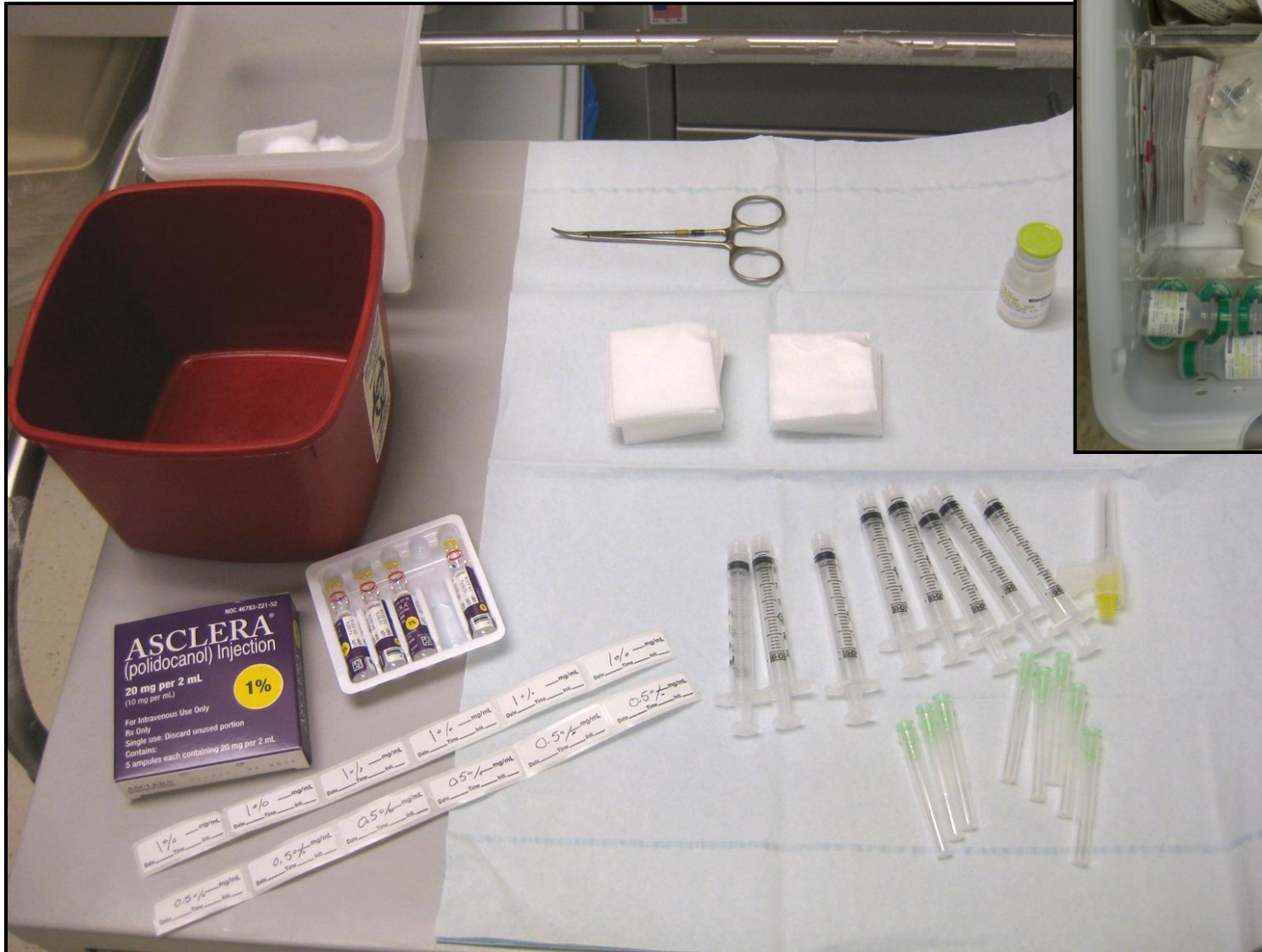
Syris[®] Head Lamp – to 1 mm





8. Use proper technique.

Set-Up



Sclerotherapy Technique: Reticular Veins



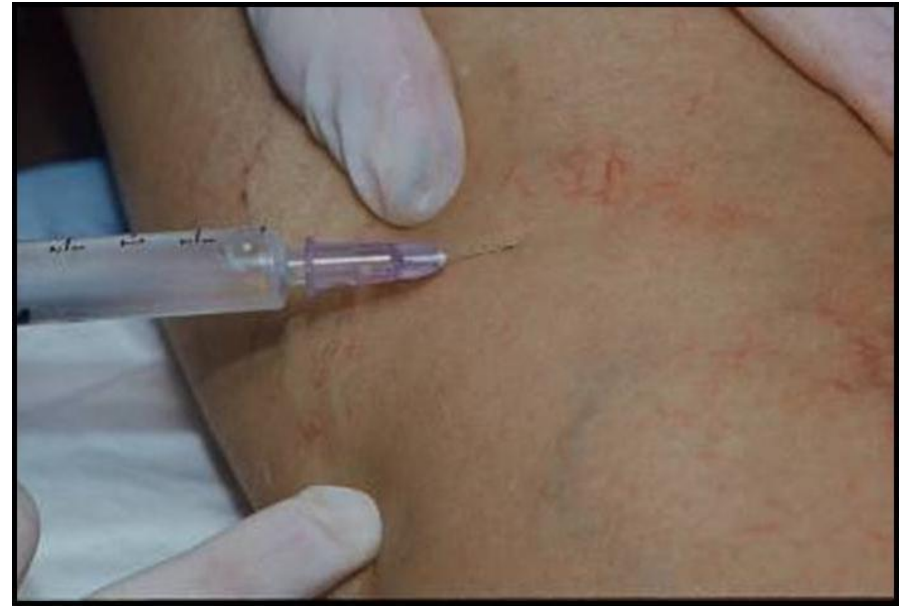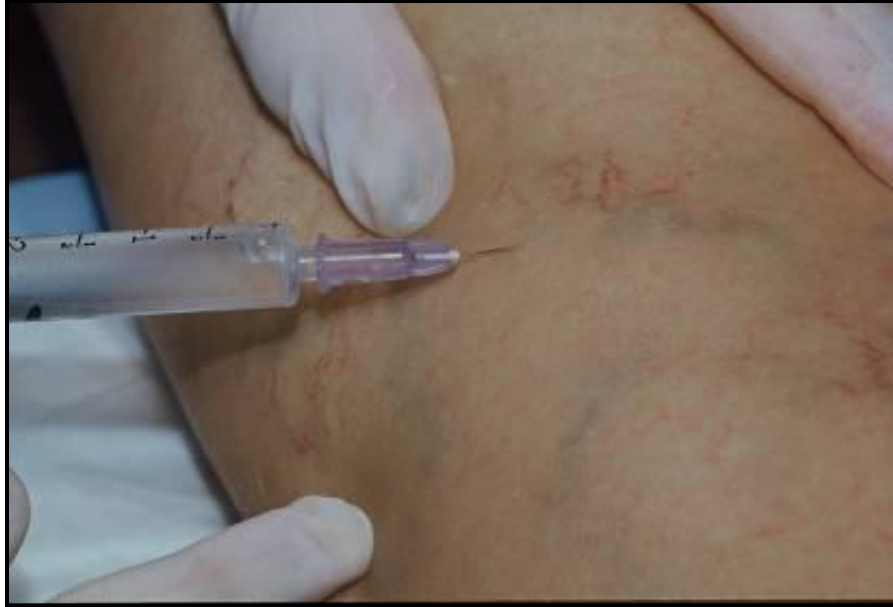- Patient is in horizontal position, legs elevated
- Angle of entry is 15-45 degree angle depending on depth
- Aspirate venous blood
- Gently and slowly inject sclerosant
- Push sclerosant until you see the vein disappear with vein lite or viewer
- Use STS 0.25% to 0.5%; POL 1.0%
- Use of foam effectively increases the concentration
- Place compression dressing before lowering legs

Sclerotherapy Technique: Spider Veins



- Use 30 gauge needle
- Angle of entry is 15-45 degree angle depending on depth
- Bevel up
- Barely insert the needle under the skin
- Do not aspirate
- Gently push sclerosant until you see disappearance of the vein OR a wheal
- If you have a wheal/bleb you have extravasated
- Use STS 0.07% to 0.25%; POL 0.5%
- Use lowest around ankle – 0.07% - 0.15%
- Place compression dressing before lowering legs

Sclerotherapy Technique: Liquid Injection



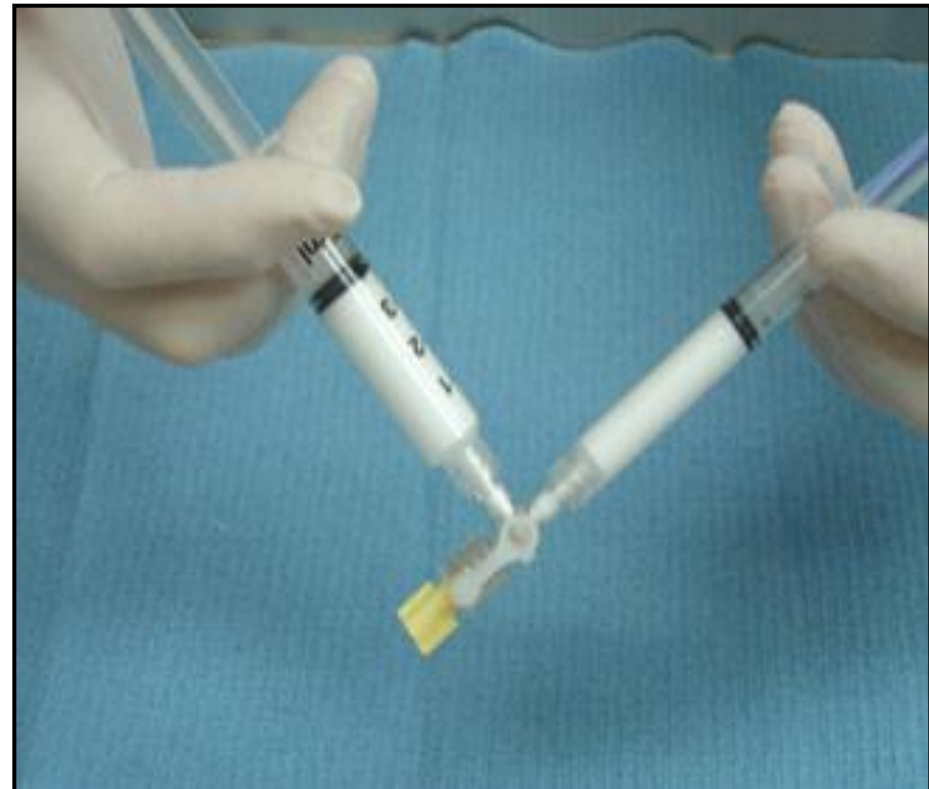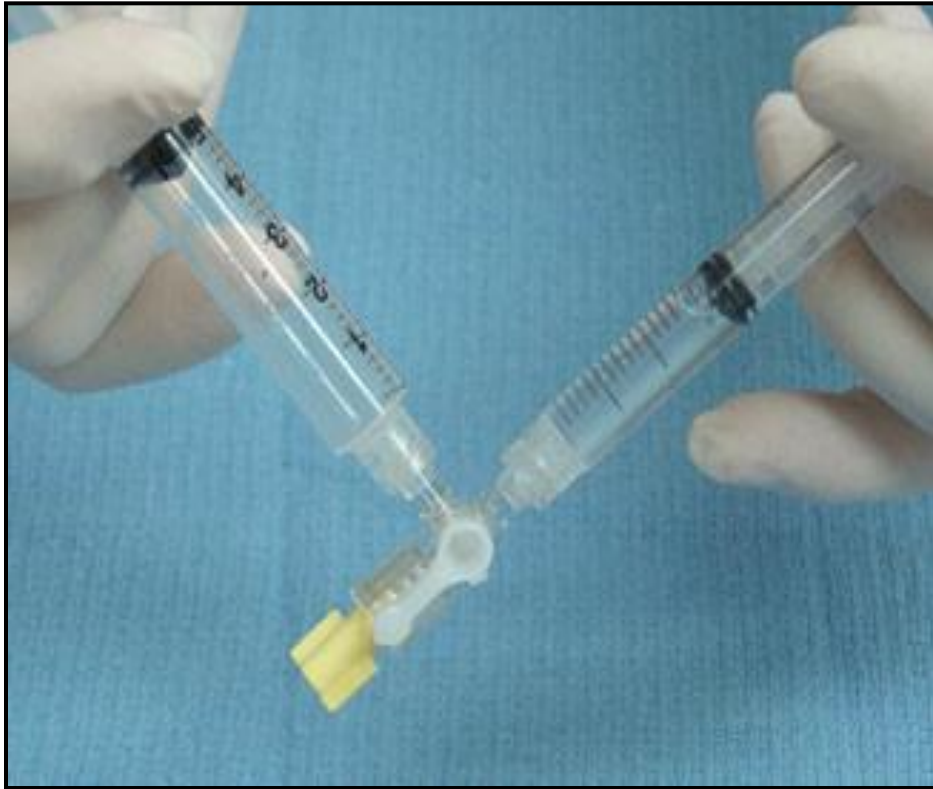Injection of sclerosant solution causes damage to endothelium which leads to fibrosis of vein

Sclectherapy Technique: Foam Sclectherapy



- Transfer 1-2 cc of sclerosant and 3-4 cc room air through a 2-way female-to-female stopcock, fast transfer ~ 20 times to create foam
- Need to re-foam after 30-60 seconds
- Foam is in contact with the endothelium long enough to induce venospasm and destroy it
- Increases efficacy of lower concentration solution
- Foam may rupture smaller spider veins causing extravasation, therefore not recommended for these

Sclerotherapy Technique: Foam Sclerotherapy



Assessment of Treatment



- If injected into the vein, the vein should disappear both to the naked eye and on the vein lite / viewer
- Within a few minutes as the vein refills it turns bright red due to inflammation
- If you have no disappearance of the vein, no red color change, or only a wheal then you have missed the vein



9. Use compression post-injection.

Post-Sclerotherapy



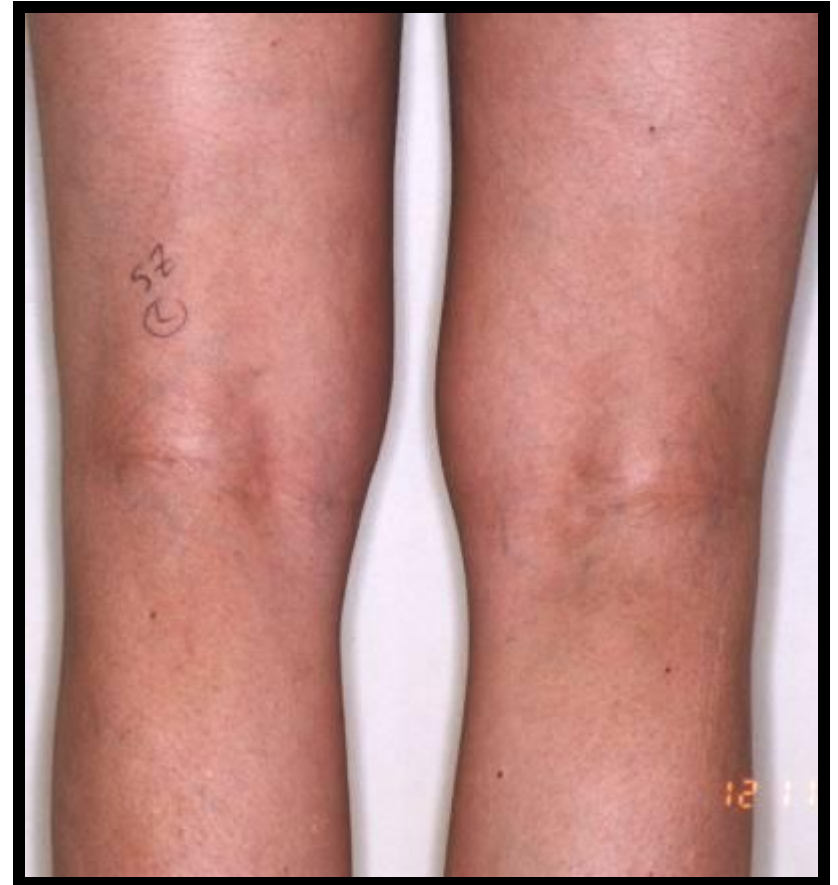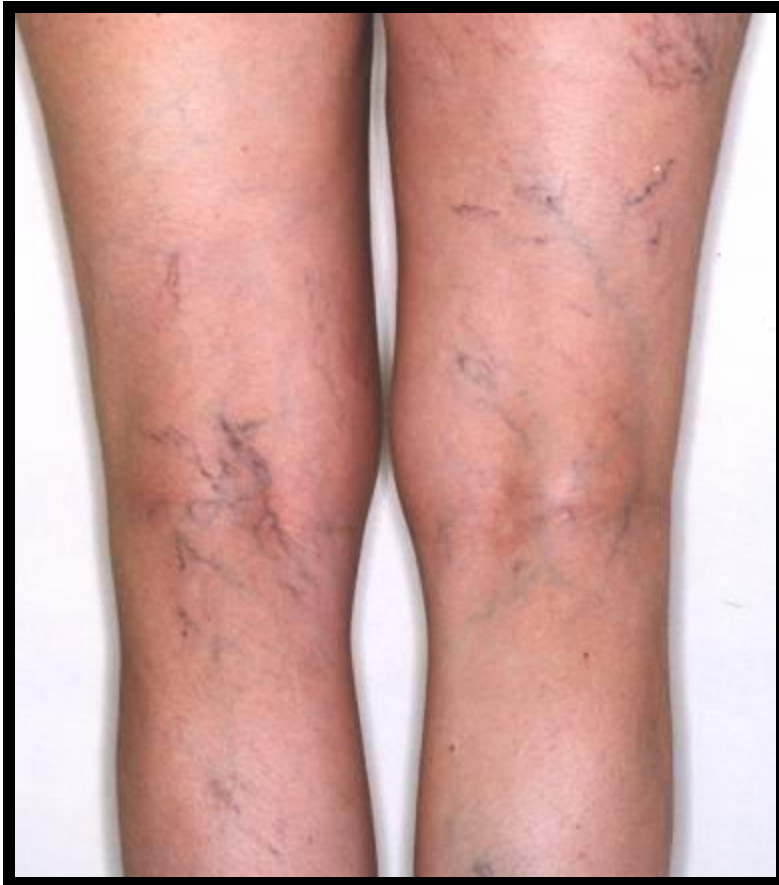- Compression hose 20-30 mmHg immediately, covering all injected areas. May use ace wraps, or compression bandages for prominent areas
- Ambulate immediately after injections
- Leave all in place for 48 hours, including for sleep, avoid vigorous workouts
- May remove bandages/hose, shower, and resume aerobic exercise in 48 hours; avoid hot baths
- Use compression hose during day for 1-2 weeks
- Avoid sun exposure for 4-6 weeks

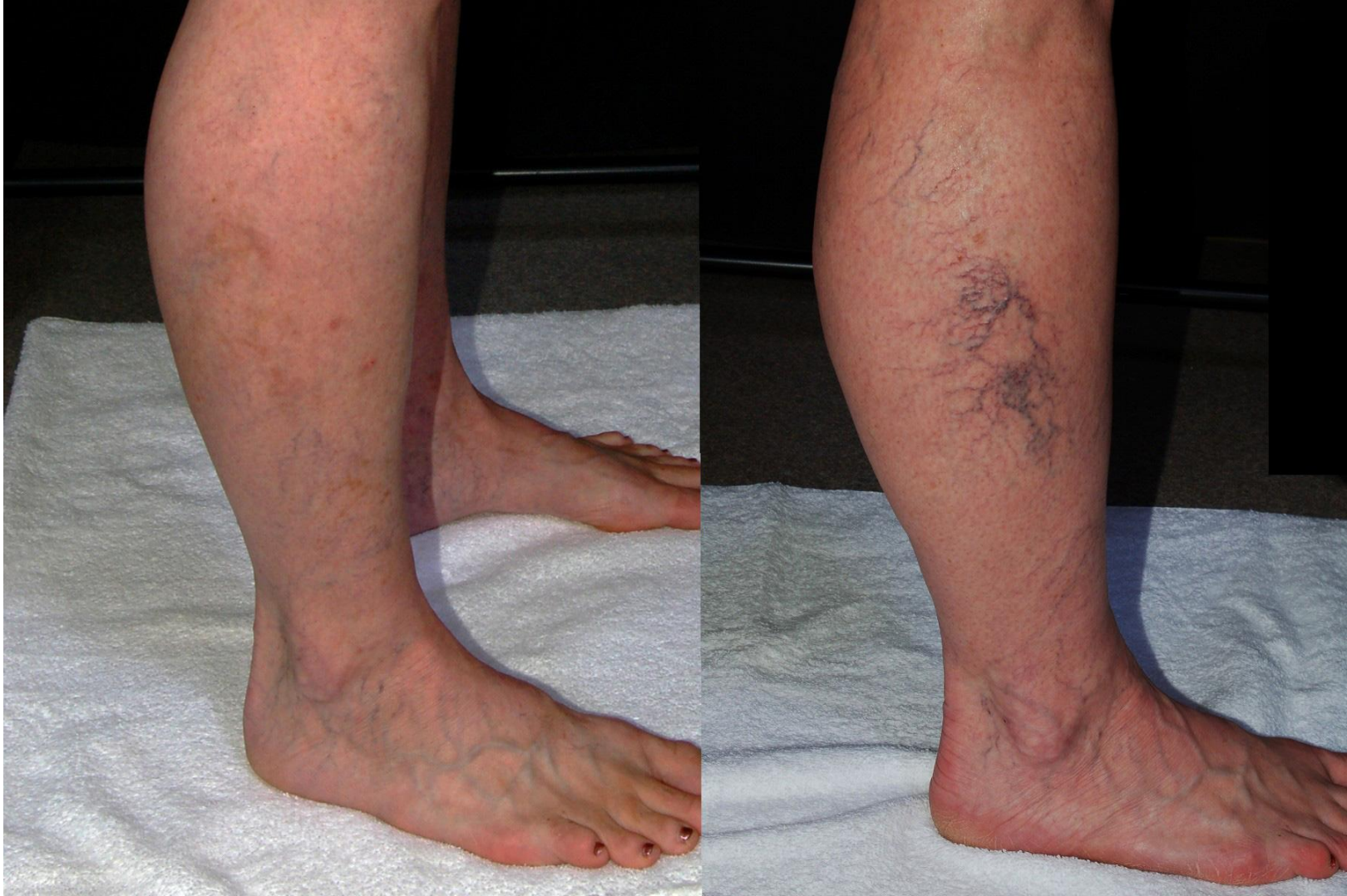

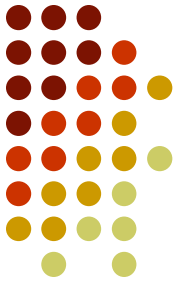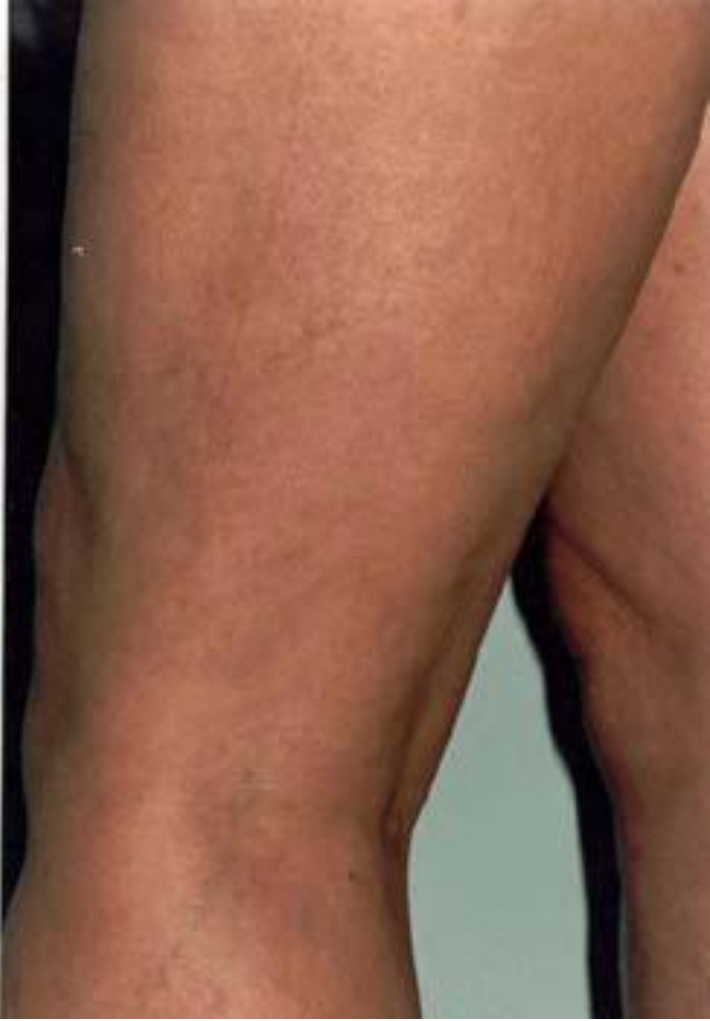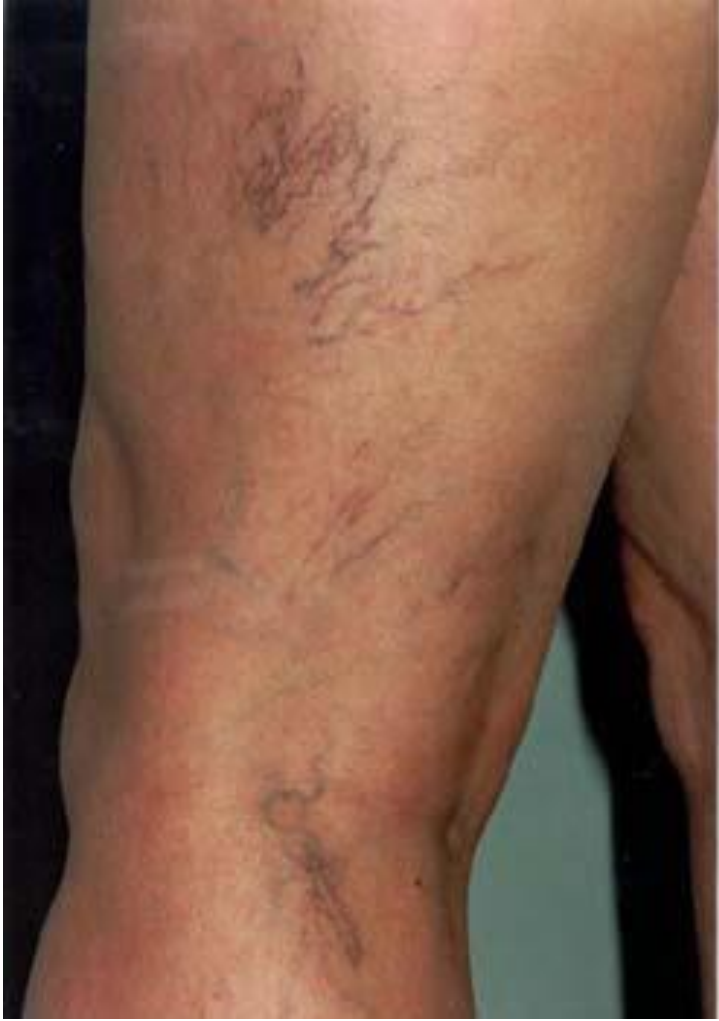Evolution of the Vein Post-Sclero

- First day: Wheals, redness will disappear after 1-2 days
- Bruising for 1-3 weeks
- If small hematomas are present, may be drained at 2-3 week for faster resolution
- May be brownish discoloration from hemosiderin deposits post-sclerotherapy
- After a few weeks, veins should look thrombosed or disappear

Sclerotherapy Results









10. Handle complications.

Sclerotherapy Complications

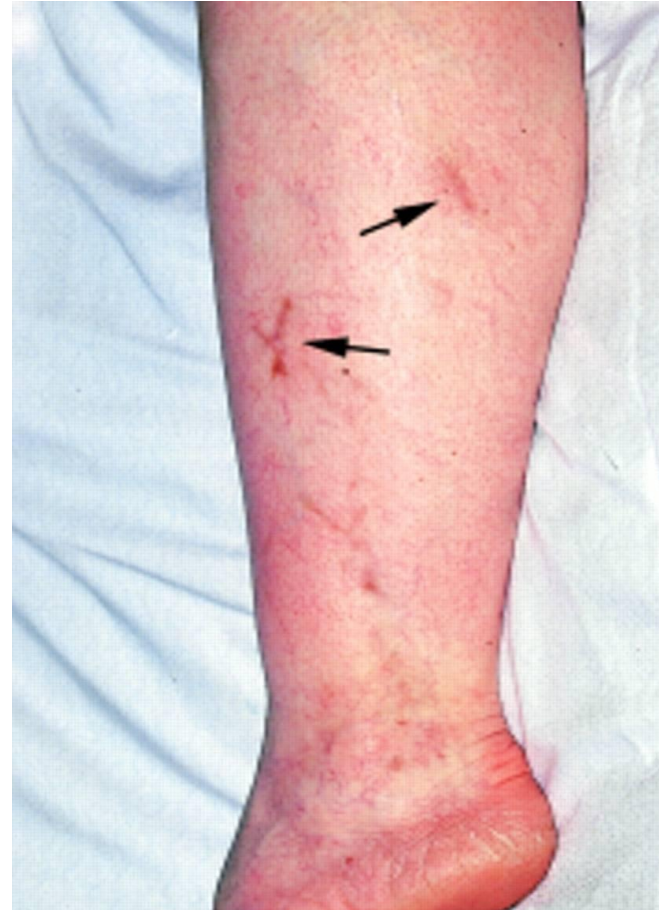

- Minor:
 - Hyperpigmentation
 - Matting
 - Urticaria
 - Hematoma
 - Extravasation
- Major:
 - Ulceration
 - Thrombus/Phlebitis
 - DVT/Pulmonary Embolism
 - Allergic Reaction

Sclerotherapy Complications



- Hyperpigmentation:
 - Brownish discoloration
 - Hemosiderin staining
 - Usually fades in 6-12 mos
 - May use IPL, hydroquinone to treat
 - Tincture of Time
- To Prevent:
 - Use lowest concentration
 - No extravasation
 - Use compression
 - Avoid NSAIDs prior
 - Remove any thrombus



Sclerotherapy Complications




- **Matting:**
 - Blush of fine, red telangiectasias
 - Can try one session at low concentration, volume, pressure
 - Transdermal laser or IPL might be helpful
 - If no resolution, do not treat for one year, ~90% resolve
- **Extravasation:**
 - Massage the bleb
 - Apply compression immediately
- **Urticaria:**
 - Self-limited, usually resolves quickly, more prominent with POL
 - Avoid extravasation into the skin
 - May use antihistamine if persistent

Sclerotherapy Complications



- Hematoma:
 - May become phlebitic
 - Evacuate thrombus at 2-3 weeks to avoid long-term dark nodule
- Ulceration:
 - Rare, related to extravasation or intraarterial injection, excessive compression
 - Treat promptly, prevent infection
- DVT, PE:
 - Extremely rare, usually large volume soln, near deep veins or injection of major vein
 - Identify patients at risk for thrombosis, ambulate frequently
- Allergy:
 - Rare, but reported. Have diphenhydramine, epinephrine, methylprednisolone, oxygen, airway available.



Art by Joslyn Doerge

~Thank You~

lorraine.loretz@umassmemorial.org